

Fractal dimension and white matter changes in multiple sclerosis

Francisco J. Esteban,^{a,*} Jorge Sepulcre,^b Nieves Vélez de Mendizábal,^{b,c} Joaquín Goñi,^{b,d}
Juan Navas,^e Juan Ruiz de Miras,^f Bartolome Bejarano,^b Jose C. Masdeu,^b and Pablo Villoslada^b

^aDepartment of Experimental Biology, Systems Biology and Neurodynamics Unit, Faculty of Experimental and Health Sciences, University of Jaén, Campus Las Lagunillas s/n, 23071, Jaén, Spain

^bCenter for Applied Medical Research and Department of Neurology and Neurosurgery, University of Navarra, Pamplona, Spain

^cDepartment of Computational Sciences and Artificial Intelligence, University of the Basque Country, San Sebastian, Spain

^dDepartment of Physics and Applied Mathematics, University of Navarra, Pamplona, Spain

^eDepartment of Mathematics, University of Jaén, Jaén, Spain

^fDepartment of Computer Science, University of Jaén, Jaén, Spain

Received 27 October 2006; revised 13 March 2007; accepted 19 March 2007

Available online 10 April 2007

The brain white matter (WM) in multiple sclerosis (MS) suffers visible and non-visible (normal-appearing WM (NAWM)) changes in conventional magnetic resonance (MR) images. The fractal dimension (FD) is a quantitative parameter that characterizes the morphometric variability of a complex object. Our aim was to assess the usefulness of FD analysis in the measurement of WM abnormalities in conventional MR images in patients with MS, particularly to detect NAWM changes. First, we took on a voxel-based morphometry approach optimized for MS to obtain the segmented brain. Then, the FD of the whole grey–white matter interface (WM border) and skeletonized WM was calculated in patients with MS and healthy controls. To assess the FD of the NAWM, we focused our analysis on single sections without lesions at the *centrum semiovale* level. We found that patients with MS had a significant decrease in the FD of the entire brain WM compared with healthy controls. Such a decrease of the FD was detected not only on MR image sections with MS lesions but also on single sections with NAWM. Taken together, the results showed that FD identifies changes in the brain of patients with MS, including in NAWM, even at an early phase of the disease. Thus, FD might become a useful marker of diffuse damage of the central nervous system in MS.

© 2007 Elsevier Inc. All rights reserved.

Keywords: Fractal dimension; Multiple sclerosis; Normal appearing white matter; Image analysis; Magnetic resonance imaging

Introduction

Multiple sclerosis (MS) is a chronic inflammatory and neurodegenerative disease of the central nervous system (CNS) (Steinman,

2001). Several pathological processes affect white matter (WM) diffusely, including areas without classical demyelinating plaques, the so-called normal-appearing white matter (NAWM). The underlying histopathological changes of NAWM are not well known, but some identified processes are microscopic inflammatory cell infiltration, microglial activation, blood-vessel sclerosis, Wallerian degeneration of axons, astrocytic proliferation, and microscopic demyelinated and remyelinated areas (Allen and McKeown, 1979; Trapp et al., 1998). NAWM abnormalities become more pronounced with increasing physical and cognitive disability and may develop for many months or even years prior to focal-lesion development (Miller et al., 2003). Thus, the detection of markers corresponding to NAWM abnormalities is clinically relevant because these abnormalities contribute to tissue damage and to the increase of long-term clinical disability, regardless of the presence of typical macroscopic MS lesions (Filippi et al., 1995, 1999; Loevner et al., 1995).

A magnetic resonance (MR) technique sensitive for detecting and quantifying the subtle neuropathological changes taking place in the NAWM is the magnetization transfer ratio (MTR). Low MTR has been associated with the main pathological changes on clinically isolated syndrome (CIS) and relapsing–remitting MS (RRMS) patients (Filippi et al., 1995, 1998; Griffin et al., 2002; Loevner et al., 1995). In addition, MTR abnormalities detected in the NAWM have recently been associated with disability in other forms of MS (Ramio-Torrenta et al., 2006). However, focal lesions had been described as the predominant pathological feature in CIS patients instead of diffuse NAWM alterations (Brex et al., 2001). The lack of MTR sensitivity to the subtle NAWM pathological changes taking place in these patients and the appearance of difficulties in the standardization of this technique preclude the generalization of its use. Another approach for studying NAWM is magnetic resonance spectroscopy (MRS). Several studies using MRS in patients with MS have shown a decrease in the *N*-acetyl

* Corresponding author. Fax: +34 953211875.

E-mail address: festeban@ujaen.es (F.J. Esteban).

Available online on ScienceDirect (www.sciencedirect.com).

aspartate peak both in MS plaques as well as in NAWM (Miller et al., 2003), suggesting that axonal disruption contributes to the abnormalities in the NAWM.

Images representing morphologically complex objects may be described and categorized using fractal analysis approaches on the value of the fractal dimension, with widespread applications in the field of neuroscience (Fernández and Jelinek, 2001). Fractal dimension (FD) is a quantitative measure of morphological complexity, and it has been stated as a good descriptor of the complex shape of cerebral structures such as the WM and grey matter (GM) in humans (Blanton et al., 2001; Free et al., 1996; Kiselev et al., 2003; Liu et al., 2003; Thompson et al., 1996). Moreover, brain FD is altered by the presence of diseases such as psychiatric disorders (Bullmore et al., 1994; Ha et al., 2005), epilepsy (Cook et al., 1995), and even age-related WM abnormalities (Kedzia et al., 1997; Takahashi et al., 2004; Zhang et al., in press). FD analysis provides complementary information to classical brain atrophy quantification in terms of surface (Ha et al., 2005; Zhang et al., in press) and internal shape complexity (Zhang et al., 2006, in press).

The aim of our study was to assess the usefulness of FD as a measurement of visible and non-visible WM abnormalities in conventional MR sequences of patients with MS. Indeed, we sought to develop a simple method for identifying additional changes of WM abnormalities in MS in order to provide a useful test for monitoring disease. We found a decrease of the WM FD in patients with MS compared to healthy controls (HC), even in sections without the presence of MS plaques.

Materials and methods

Patients

A total of 60 cases and 17 gender- and age-matched healthy controls (HC) were recruited in the MS centre of the University of Navarra (Spain). All subjects gave their informed consent according to the Helsinki Declaration before being included in the study, which was approved by the local Research Ethics Committee. Twenty-one patients suffered CIS, 31 RRMS, four secondary progressive MS (SPMS), and four primary progressive MS (PPMS) (McDonald et al., 2001). Patients with an active relapse, or who were taking steroids or who had suffered a clinical relapse within the previous 2 months were excluded. MS-related

disability was clinically assessed using the Extended Disability Status Scale (EDSS) (Kurtzke, 1983) and the MS Functional Composite (MSFC) (Fischer et al., 1999). Demographic, clinical, and MR image data of the subjects are shown in Table 1.

MR acquisition

In the following month of neurological assessment, an MR imaging study was performed on a 1.5-T SIEMENS SYMPHONY scanner (Erlangen, Germany). A T1-weighted MR sequence (TR 2.14 ms, TE 5.04 ms, flip angle 15°; 256×256 matrix size; 48 contiguous 3-mm axial slices; 25-cm FOV; in-plane resolution of 0.5×0.5) and a 3D proton density/T2-weighted sequence (TR 3700 ms, TE 29 ms, turbo factor 5; 256×256 matrix size; 48 contiguous 3-mm axial slices; 25-cm FOV; in-plane resolution of 0.5×0.5) were used to acquire high-resolution volumetric images.

Brain segmentation and volume of lesions

A modified version of the optimized voxel-based morphometric (VBM) protocol (Good et al., 2001) was used by a trained operator (JS) in order to obtain the segmented WM images from each subject's MR, while avoiding the bias introduced by MS-related lesions (Sepulcre et al., 2006). In brief, a 3D binary MS lesion mask in native space was created at the voxel level for each patient, using the MRIcro software (Chris Rorden, University of Nottingham, Great Britain; <http://www.sph.sc.edu/comd/rorden/mricro.html>). Two independent observers (JS and JCM) outlined all the WM lesions on each slice of the MR image scan of each subject, with excellent inter-rater reliability (intra-class correlation coefficient=0.892 ($p<0.001$)). For the following stages, we used the SPM2 software (Wellcome Department of Cognitive Neurology, University College of London, London, UK) running under Matlab v6.5 (MathWorks Inc., Natick, MA). Our own customized whole brain T1 template and GM, WM, and cerebrospinal fluid (CSF) prior probability maps were first generated. This procedure is introduced in neuroimaging studies in order to avoid scanner- and population-specific bias (Good et al., 2001). The T1 images were spatially normalized into the same stereotactic space using the MNI (Montreal Neurological Institute) template, and re-sliced to 1-mm isotropic voxels. The normalization was done by first estimating the optimum 12-parameter affine transformation for matching images, and then optimizing the normalization using 16 non-linear

Table 1
Demographic, clinical, MR image data of subjects

	CIS (n=21)	RRMS (n=31)	SPMS (n=4)	PPMS (n=4)	HC (n=17)	p value
Age (years) ^a	35.67±7.48	35±9.73	45.5±9.95	41.25±5.9	36.7±8.99	ns
Sex ratio (M/F)	7/14	9/22	1/3	3/1	7/10	ns
Disease duration (years) ^b	0.91 (0.16 to 2.67)	7.08 (0.83 to 36)	19.5 (14 to 21)	3.29 (2 to 6.33)	–	–
EDSS score ^b	1.5 (0 to 4.0)	2.91 (0 to 6.0)	5.25 (5.0 to 7.0)	3.25 (2.5 to 4.0)	–	–
MSCF score ^b	0.32±0.59	0.04±0.8	−0.92±0.7	0.07±0.55	–	–
T2 lesion load (cm ³) ^b	15.46 (1.2 to 106.41)	51.27 (4.46 to 175.88)	20.02 (3.77 to 47.27)	27.81 (5.24 to 111.99)	–	–
T1 lesion load (cm ³) ^b	4.48 (0.08 to 83.82)	12.37 (1.05 to 96.36)	12.95 (1.36 to 25.04)	14.81 (4.21 to 48.51)	–	–
Fractal dimension	1.325±0.017	1.331±0.020	1.315±0.030	1.331±0.018	1.358±0.020	<0.05 ^c
Fractal dimension skeletonized	1.056±0.026	1.059±0.024	1.048±0.019	1.060±0.010	1.073±0.021	<0.05 ^c

CIS: clinical isolated syndrome; RRMS: relapsing remitting multiple sclerosis; SP: secondary progressive multiple sclerosis; PP: primary progressive multiple sclerosis; HC: healthy controls; EDSS: expanded disability status scale; MSFC: MS functional composite. The data are expressed in mean±standard deviation^a or median (range)^b depending on the parametric or non-parametric distribution of the variable. ^cSee Results for details. –: not applicable.

iterations (Ashburner and Friston, 1999). Following this protocol, all patients' scans were weighted by the corresponding MS-lesion masks in the normalization and segmentation procedures. In every segmentation and normalization step of this protocol, we applied a lesion mask function to mask regions containing visible lesions (Sepulcre et al., 2006). The customized T1 template and GM, WM, and CSF prior probability maps were used in the segmentation of the T1 scan of each subject in order to obtain GM, WM, and CSF images in native space (again using MS-lesion masks to weight the images and avoid misclassifications of tissue). The optimized parameters determined earlier were then applied to the original T1 volumes in native space and the resulting optimally normalized T1 images were finally segmented to produce the GM, WM, and CSF maps in MNI space. Finally, all images were smoothed using a 12-mm FWHM isotropic Gaussian filter (Good et al., 2001).

For each patient, we measured the total volume of WM-lesion load on T1 and T2 studies using the MRIcro software. We calculated the total lesion volume in each patient by multiplying the total number of lesion voxels by the size of the voxel.

Fractal analysis method

The FD of the entire brain was determined, section by section, from whole segmented WM in each subject. For the NAWM analysis, we chose one particular slice at the *centrum semiovale* level (single-slice analysis). First, we selected the first segmented WM axial slice above ventricular space, and later, each selected slice was classified as affected or unaffected by MS lesions on the basis of visual observation of two researchers (JS and JCM; 0.883 Kappa coefficient; $p < 0.001$).

We opted for the traditional box-counting method, using HarFA v5.2 software (<http://www.fch.vutbr.cz/lectures/imagesci/>), because it can evaluate the FD of structures without self-similarity (the brain is not strictly self-similar; Zhang et al., 2006). Briefly, to estimate FD, we divided the Euclidean space containing the image into a grid of boxes of size r . The r was then made progressively smaller and the corresponding number of nonempty boxes (N) that covered the object was counted (Fig. 1); the log–log plot of $\ln N$ versus the $\ln(1/r)$ gives a line with a slope that corresponds to FD (Fig. 2). Details of the method and its applications can be found elsewhere (Zhang et al., 2006).

Each segmented WM image (Fig. 1A) was processed in two ways and, thus, two values of FD were calculated, depending on the processing approach: (i) the FD from original images that were loaded onto HarFA v5.2, and here binary converted after performing a full-range thresholding to exclude just the black background (intensity selection from 1 to 255) (Fig. 1B); (ii) the FD of these previously processed binary images but after applying a skeletonization algorithm using ImageJ software (<http://rsb.info.nih.gov/ij/>) (Fig. 1C), since the WM shape is also well represented by its skeleton (Zhang et al., 2006). Whereas the FD of the first set of images enabled us to characterize the complexity of the WM border (Figs. 1D, F), the FD established from the skeletons represented the complexity of the WM structure (Figs. 1E, G). Taking into account that the brain images studied here were not pure fractals, an appropriate range of box sizes must be selected. So, if the size of the overlaid boxes is too small, a mosaic composed of white-and-black pixels (not the complex object) will be obtained; but, if the box size is too large, the object to be analyzed disappears in the white background. An inappropriate range of box sizes is detected as a disturbance of linearity in the

linear regression analysis carried out to derive the FD, which requires the linear part of the function (Fig. 2). Using the slope analysis procedure implemented in HarFA v5.2, we obtained as appropriate box sizes for all full thresholding images, from 3 to 20 pixels (to apply both at the general and at the *centrum semiovale* level analyses), and for skeletonized images, from 3 to 12 pixels in the general analysis and from 3 to 15 pixels when the specific *centrum semiovale* level analysis was carried out. Details of the method, including single slope analysis, and its applications to obtain the FD of white matter MR images can be found elsewhere (Zhang et al., 2006).

Statistical analysis

We used the Shapiro–Wilk test to determine the normal distribution of our variables. The Kruskal–Wallis and Mann–Whitney U tests were implemented to compare the FD values between subjects groups. Pearson's or Spearman's correlation tests were applied to assess univariate correlation depending on parametric or non-parametric distribution of the variables. The level of significance for the results was set at $p < 0.05$. These analyses were carried out using the statistical package SPSS v13.0 (SPSS Inc., Chicago, Illinois).

Results

We compared the FD of the WM border between HC and MS patients. We found that patients with MS had a decrease of the FD of the WM border compared to HC ($p < 0.001$; Fig. 3A). In addition, we attained the same decrease in the FD of the WM border for all subtypes of MS ($p < 0.05$ in all cases; Fig. 3B). To evaluate the influence of the presence of macroscopic MS lesions and the NAWM abnormalities on the FD calculation, we quantified the FD in patients with and without visible MS lesions at the supraventricular section of the *centrum semiovale* (single-slice analysis). Again, we found a decrease in the FD of the WM border in patients with and without lesions (NAWM) compared to HC ($p < 0.05$ in both cases, Fig. 3C).

Currently, it is unknown to what extent the NAWM is already damaged early in the course of the disease such as in CIS patients or whether this damage evolves over time, contributing to clinical disability worsening. Thus, to assess the state of NAWM at the early phase of MS, we compared the FD between CIS patients and HC, both in sections with and without MS lesions. CIS patients had decreased FD in slices with or without lesions (NAWM) in the single-slice analysis ($p < 0.05$ in both cases; Fig. 3D).

Since the FD analysis of the skeletonized binary volume data provides additional information of the internal structure of the WM, this parameter was assessed in our population. We found a decrease in the skeletonized FD between patients with MS and HC ($p = 0.009$; Fig. 4A). We also got a decrease in the skeletonized FD when comparing HC and disease subtypes, except for PPMS patients ($p < 0.05$ in all cases; Fig. 4B). In the NAWM sub-analysis (single-slice analysis), only patients with plaques in the studied section had a significant decrease in skeletonized FD compared to HC ($p < 0.05$ in all cases; Figs. 4C and D).

Concerning lesion load, we found a correlation between WM skeletonized FD and lesion volume, both on T1 ($r = -0.324$, $p = 0.028$) and T2 ($r = -0.320$, $p = 0.013$). The presence of NAWM has been claimed to explain the clinical–radiological paradox in MS. For this reason, we were also interested to know whether the

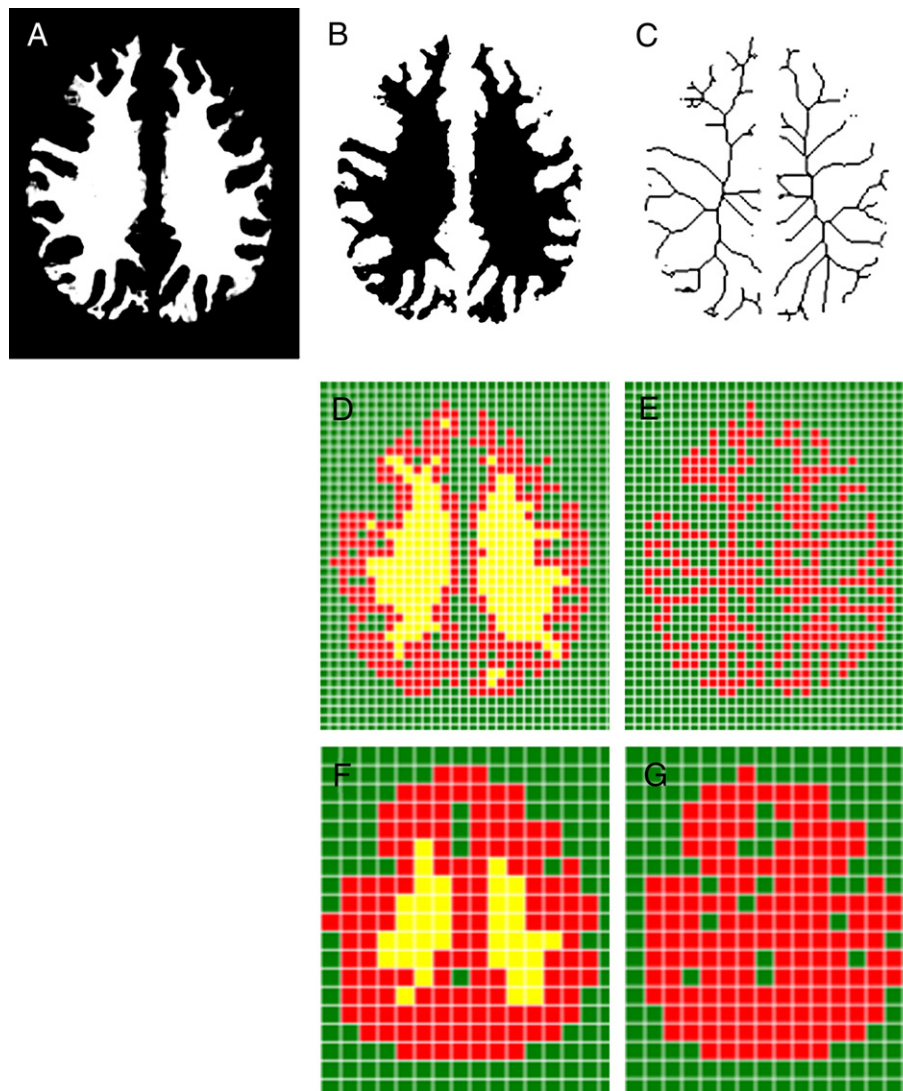


Fig. 1. Box-counting method used to obtain the fractal dimension of MR images (data from one control subject) using HarFA software (<http://www.fch.vutbr.cz/lectures/imagesci>). (A) White matter image at the *centrum semiovale* level obtained after segmentation with SPM2. (B) Binary converted image from (A) after performing a full-range thresholding to exclude the black background (intensity selection from 1 to 255). (C) *Skeletonized* image obtained from (B) after applying a skeletonization algorithm. (D–G) A grid with different number of boxes (N) covered each image depending on the box size (r): (D) White matter border, $r=5$ pixels, $N=315$ (red boxes). (E) Skeleton, $r=5$ pixels, $N=323$ (red boxes). (F) White matter border, $r=10$ pixels, $N=133$ (red boxes). (G) Skeleton, $r=10$ pixels, $N=153$ (red boxes).

changes in the FD would be associated with the degree of disability. Nevertheless, we found no associations between EDSS or MSFC scores and FD values.

Discussion

One prominent finding of this study was that WM FD is decreased in patients with MS, both at the grey–white matter boundary (WM border) and at the internal structure of the WM (WM skeleton) of the entire brain. Such decrease in the FD was an early event in the disease and was influenced not only by the presence of MS plaques but also by changes in the NAWM. Indeed, the implementation of a simple approach, such as determining the FD on a single slice of WM segmented from a conventional MR image, is informative for identifying WM

abnormalities, including the subtle changes in NAWM that occur in MS. Thus, FD allows us to detect some fundamental differences in brain architecture, providing a global measurement of morphological changes induced by neurological diseases such as MS.

Several pathological events might contribute to the decrease of the FD. Although from a mathematical point of view it has not been demonstrated whether the direction of the FD change in 3D structures indicates an increase or a decrease in the complexity of the object, it has been suggested that a decrease in FD would point out to a lower morphological complexity (e.g. a more amorphous structure). In relation to the magnitude of the differences, it must be noticed that small changes in the FD value correspond to big differences in the shape of the object, because of the logarithmic calculation of the FD. Since the three-dimensional structure of the WM pathways is highly organized, we hypothesize that axonal

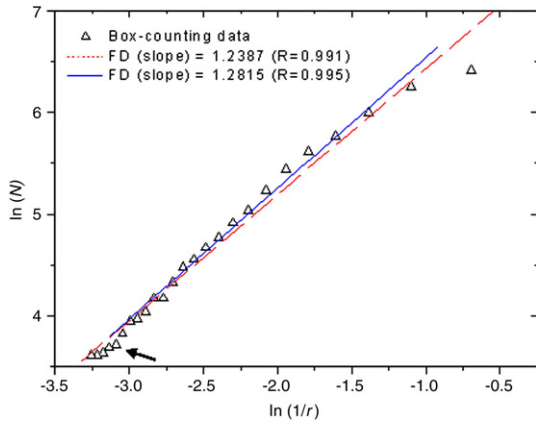


Fig. 2. Plot of $\ln N$ (number of boxes containing the object) versus $\ln(1/r)$ (size in pixel of the box) gives a line with a slope that corresponds to FD (control subject). Taking into account the non-linear part of data (arrow), linear regression analyses were carried out, where the solid line corresponds to the chosen box sizes (from 3 to 20, in this case), and the dashed line corresponds to the whole box size data.

loss could be the main contributor to the decrease of FD. Moreover, increased water content, a decreased myelin content and other inflammatory events can also participate in the generation of a more amorphous tissue contributing to the decrease of FD. In addition, the decrease of FD at the WM border can be due to both juxtacortical WM lesions and grey

matter abnormalities that are not seen on conventional MR image studies. Nonetheless, only comparative studies between MR image FD analysis and anatomical FD analysis using postmortem tissue from MS patients can clarify the morphological basis of FD decrease in MS brains.

The pathological changes in NAWM of MS are still not well understood; however, several processes are known to contribute to the abnormalities. One such process is Wallerian degeneration from transected axons in distant MS lesions (Evangelou et al., 2000; Miller et al., 2003; Bjartmar et al., 2001; Trapp et al., 1998). Another mechanism is the presence of microscopic lesions, including perivascular inflammatory lesions and areas of demyelination that are not visible on conventional MR images (Allen et al., 2001; De Groot et al., 2001), shadow plaques (Lassmann, 2005), activated microglia, edema, or myelin loss (Allen and McKeown, 1979; Trapp et al., 1998). In summary, because the WM is a highly structured tissue, most of the pathological processes described above can disturb its architecture and bring on areas of amorphous tissue, which will have a heavy impact on several measures of brain topology, such as MTR (Filippi et al., 1995), diffusion-tensor imaging (Ciccarelli et al., 2003; Filippi and Inglese, 2001), or FD, as in the present study. However, given the varied physical basis of each technique, it is likely that all of them measure different features with different morphological substrates.

In our study, we found that FD was decreased in patients with MS, even in the early phases of the disease. Such result suggests that MS is a disseminated disease of the CNS even in the early

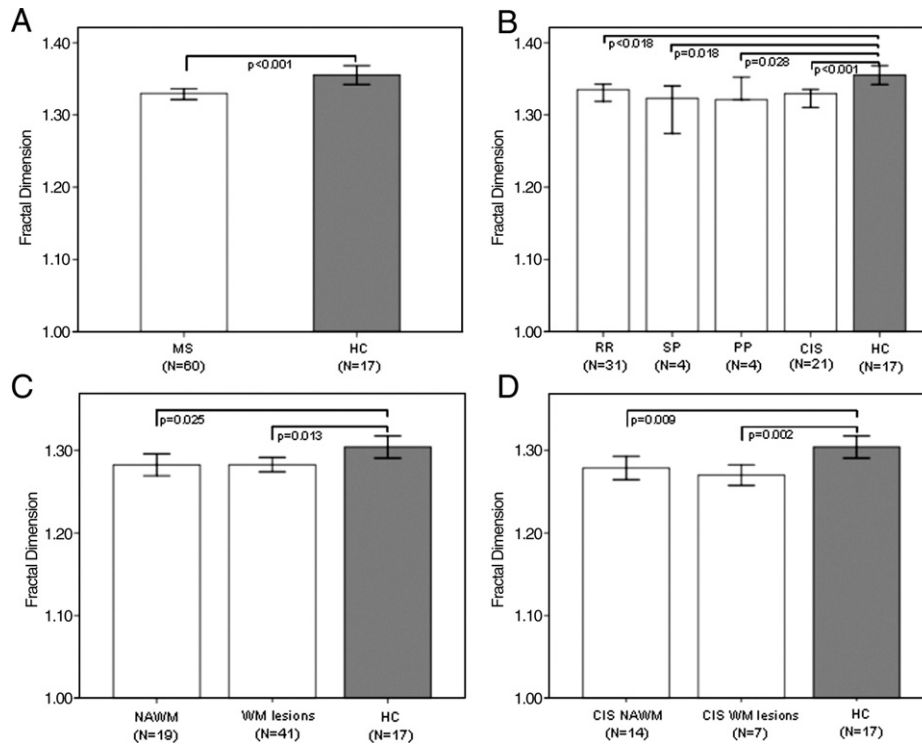


Fig. 3. Fractal dimension comparison of the grey–white matter interface (white matter border) corresponding to the full-range thresholded images from controls and patients. (A) Patients with MS have smaller FD of the entire brain than HC. (B) Comparison of the FD analysis between disease subtype and HC. (C) Comparison of the FD between patients without presence of lesions on the MR image at the single-slice level of the analysis (*centrum semiovale*) (NAWM group), patients with presence of lesions on the MR image at such level (WM lesions group), and HC (single-slice analysis). (D) Comparison of the FD between CIS patients without the presence of lesions on the MR image at the single-slice level of the analysis (CIS NAWM group), CIS patients with presence of lesions on the MR image at such level (CIS WM lesions group), and HC.

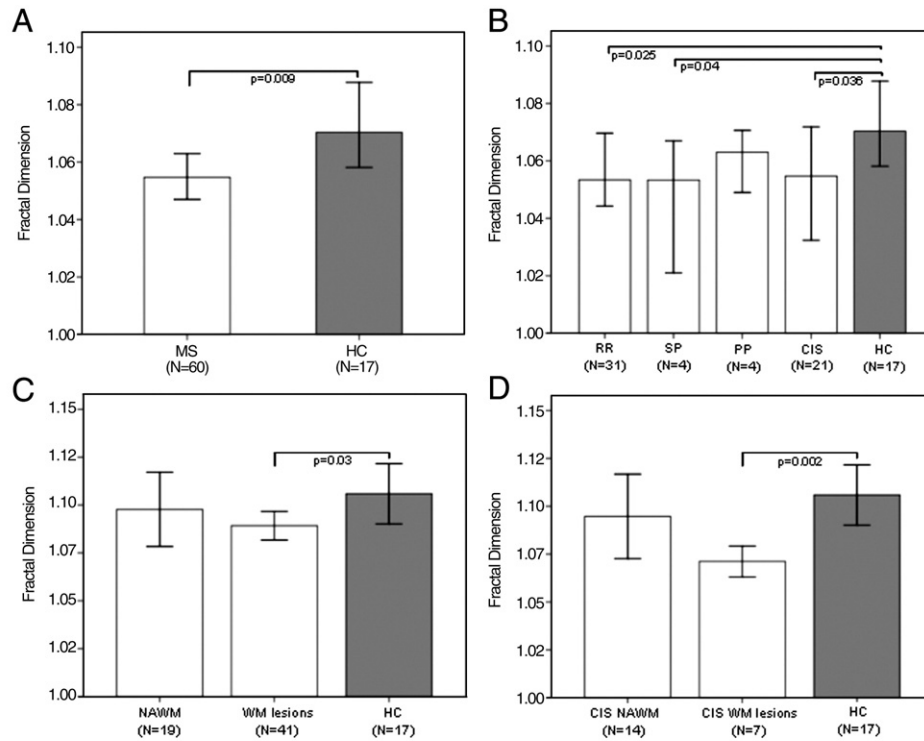


Fig. 4. Fractal dimension comparison of the *skeletonized* white matter corresponding to the full-range thresholded images from controls and patients. (A) Patients with MS have smaller FD of the entire brain than HC. (B) Comparison of the FD analysis between disease subtype and HC. (C) Comparison of the FD between patients without presence of lesions on the MR image at the single-slice level (NAWM group), patients with presence of lesions on the MR image at such level (WM lesions group) and HC. (D) Comparison of the FD between CIS patients without the presence of lesions on the MR image at the single-slice level (CIS NAWM group), CIS patients with presence of lesions on the MR image at such level (CIS WM lesions group), and HC.

course, and that such abnormalities persist overtime. However, the small sample size of patients with progressive forms of the disease prevents us from fully characterizing FD changes in patients with long-term MS. Although we found no association between FD and MS disability scales, this can be explained by several factors. First, most of the physical disability could derive from the presence of spinal cord lesions that have not been analyzed in our study. Second, FD can identify structural abnormalities with little functional implications; for example, the presence of edema can reduce FD but has little impact on nerve conduction. In addition, the functional reserve of the brain can fully compensate small decreases of axonal density in a given pathway, thereby reducing the ability to correlate morphological to functional changes. Third, FD is a global measure of brain structure, and as happens with other global MR metrics, it does not take into account whether the lesions affect clinically silent regions or pathways that have a critical role in the generation of physical disability. Finally, because differences in FD among disease subtypes were small, FD could lack power to identify changes associated with disability.

New simple and easy-to-standardize techniques are required to monitor the state of NAWM. At present, the generalized use of MTR is limited because it is difficult to standardize across multiple clinical sites; MRS has a low signal-to-noise ratio and a modest reproducibility; and MR diffusion tensor imaging is limited in areas of crossed or bent tracts (Miller et al., 2003). These shortcomings preclude the generalization of these techniques for the measurement of widespread brain damage in MS. FD analysis can yield a sensitive measure of brain-tissue abnormalities and also

evaluate their functional or clinical impact (Takahashi et al., 2004). Certainly, even small differences in FD values have a strong impact on the structure of a given object or tissue. Thus, the measurement of WM FD in MS patients could be a useful approach to assess the structural changes of WM.

Our study did not address a comparison between FD and MTR or MRS, which might have captured fresh insights in the analysis of NAWM. So, further studies are needed both to determine to what extent these results hold true for other techniques in MS patients and to identify the biological usefulness of the fractal analysis.

Acknowledgments

We would like to thank Diego Maza, from the Department of Physics of the University of Navarra for his helpful comments. This work was supported by *Junta de Andalucía* (CVI-302) to FJER, and the *Spanish Ministry of Health* (FIS PI051201) and *Fundacion Uriach* to PV. JS was a fellow of the *Spanish Ministry of Health* (FIS CM#05/00222), NVM of the *Basque Country Government* and JG of the *Navarra Government*. The authors have no conflicting financial interests.

References

- Allen, I.V., McKeown, S.R., 1979. A histological, histochemical and biochemical study of the macroscopically normal white matter in multiple sclerosis. *J. Neurol. Sci.* 41, 81–91.

- Allen, I.V., McQuaid, S., Mirakhor, M., et al., 2001. Pathological abnormalities in the normal-appearing white matter in multiple sclerosis. *Neurol. Sci.* 22, 141–144.
- Ashburner, J., Friston, K.J., 1999. Nonlinear spatial normalization using basis functions. *Hum. Brain Mapp.* 7, 254–266.
- Bjartmar, C., Kinkel, R.P., Kidd, G., et al., 2001. Axonal loss in normal-appearing white matter in a patient with acute MS. *Neurology* 57, 1248–1252.
- Blanton, R.E., Levitt, J.G., Thompson, P.M., et al., 2001. Mapping cortical asymmetry and complexity patterns in normal children. *Psychiatry Res.* 107, 29–43.
- Brex, P.A., Leary, S.M., Plant, G.T., et al., 2001. Magnetization transfer imaging in patients with clinically isolated syndromes suggestive of multiple sclerosis. *AJNR Am. J. Neuroradiol.* 22, 947–951.
- Bullmore, E., Brammer, M., Harvey, I., et al., 1994. Fractal analysis of the boundary between white matter and cerebral cortex in magnetic resonance images: a controlled study of schizophrenic and manic-depressive patients. *Psychol. Med.* 24, 771–781.
- Ciccarelli, O., Werring, D.J., Barker, G.J., et al., 2003. A study of the mechanisms of normal-appearing white matter damage in multiple sclerosis using diffusion tensor imaging-evidence of Wallerian degeneration. *J. Neurol.* 250, 287–292.
- Cook, M.J., Free, S.L., Manford, M.R., et al., 1995. Fractal description of cerebral cortical patterns in frontal lobe epilepsy. *Eur. Neurol.* 35, 327–335.
- De Groot, C.J., Bergers, E., Kamphorst, W., et al., 2001. Post-mortem MRI-guided sampling of multiple sclerosis brain lesions: increased yield of active demyelinating and (pre)active lesions. *Brain* 124, 1635–1645.
- Evangelou, N., Esiri, M.M., Smith, S., et al., 2000. Quantitative pathological evidence for axonal loss in normal appearing white matter in multiple sclerosis. *Ann. Neurol.* 47, 391–395.
- Fernández, E., Jelinek, H.F., 2001. Use of fractal theory in neuroscience: methods, advantages, and potential problems. *Methods* 24, 309–321.
- Filippi, M., Inglesse, M., 2001. Overview of diffusion-weighted magnetic resonance studies in multiple sclerosis. *J. Neurol. Sci.* 186, S37–S43.
- Filippi, M., Campi, A., Dousset, V., et al., 1995. A magnetization transfer imaging study of normal-appearing white matter in multiple sclerosis. *Neurology* 45, 478–482.
- Filippi, M., Rocca, M.A., Martino, G., et al., 1998. Magnetization transfer changes in the normal appearing white matter precede the appearance of enhancing lesions in patients with multiple sclerosis. *Ann. Neurol.* 43, 809–814.
- Filippi, M., Tortorella, C., Bozzali, M., 1999. Normal-appearing white matter changes in multiple sclerosis: the contribution of magnetic resonance techniques. *Mult. Scler.* 5, 273–282.
- Fischer, J.S., Rudick, R.A., Cutter, G.R., et al., 1999. The multiple sclerosis functional composite measure (MSFC): an integrated approach to MS clinical outcome assessment. National MS Society Clinical Outcomes Assessment Task Force. *Mult. Scler.* 5, 244–250.
- Free, S.L., Sisodiya, S.M., Cook, M.J., et al., 1996. Three-dimensional fractal analysis of the white matter surface from magnetic resonance images of the human brain. *Cereb. Cortex* 6, 830–836.
- Good, C.D., Johnsrude, I.S., Ashburner, J., et al., 2001. A voxel-based morphometric study of ageing in 465 normal adult human brains. *NeuroImage* 14, 21–36.
- Griffin, C.M., Chard, D.T., Parker, G.J., et al., 2002. The relationship between lesion and normal appearing brain tissue abnormalities in early relapsing remitting multiple sclerosis. *J. Neurol.* 249, 193–199.
- Ha, T.H., Yoon, U., Lee, K.J., et al., 2005. Fractal dimension of cerebral cortical surface in schizophrenia and obsessive-compulsive disorder. *Neurosci. Lett.* 384, 172–176.
- Kedzia, A., Rybaczuk, M., Dymecki, J., 1997. Fractal estimation of the senile brain atrophy. *Folia. Neuropathol.* 35, 237–240.
- Kiselev, V.G., Hahn, K.R., Auer, D.P., 2003. Is the brain cortex a fractal? *NeuroImage* 20, 1765–1774.
- Kurtzke, J.F., 1983. Rating neurologic impairment in multiple sclerosis: an expanded disability status scale (EDSS). *Neurology* 33, 1444–1452.
- Lassmann, H., 2005. Multiple sclerosis pathology: evolution of pathogenetic concepts. *Brain Pathol.* 15, 217–222.
- Liu, J.Z., Zhang, L.D., Yue, G.H., 2003. Fractal dimension in human cerebellum measured by magnetic resonance imaging. *Biophys. J.* 85, 4041–4046.
- Loevner, L.A., Grossman, R.I., Cohen, J.A., et al., 1995. Microscopic disease in normal-appearing white matter on conventional MR images in patients with multiple sclerosis: assessment with magnetization-transfer measurements. *Radiology* 196, 511–515.
- McDonald, W.I., Compston, A., Edan, G., et al., 2001. Recommended diagnostic criteria for multiple sclerosis: guidelines from the International Panel on the diagnosis of multiple sclerosis. *Ann. Neurol.* 50, 121–127.
- Miller, D.H., Thompson, A.J., Filippi, M., 2003. Magnetic resonance studies of abnormalities in the normal appearing white matter and grey matter in multiple sclerosis. *J. Neurol.* 250, 1407–1419.
- Ramio-Torrenta, L., Sastre-Garriga, J., Ingle, G.T., et al., 2006. Abnormalities in normal appearing tissues in early primary progressive multiple sclerosis and their relation to disability: a tissue specific magnetisation transfer study. *J. Neurol. Neurosurg. Psychiatry* 77, 40–45.
- Sepulcre, J., Sastre-Garriga, J., Cercignani, M., et al., 2006. Regional gray matter atrophy in early primary progressive multiple sclerosis: a voxel-based morphometry study. *Arch. Neurol.* 63, 1175–1180.
- Steinman, L., 2001. Multiple sclerosis: a two-stage disease. *Nat. Immunol.* 2, 762–764.
- Takahashi, T., Murata, T., Omori, M., et al., 2004. Quantitative evaluation of age-related white matter microstructural changes on MRI by multifractal analysis. *J. Neurol. Sci.* 225, 33–37.
- Thompson, P.M., Schwartz, C., Lin, R.T., et al., 1996. Three-dimensional statistical analysis of sulcal variability in the human brain. *J. Neurosci.* 16, 4261–4274.
- Trapp, B.D., Peterson, J., Ransohoff, R.M., et al., 1998. Axonal transection in the lesions of multiple sclerosis. *N. Engl. J. Med.* 338, 278–285.
- Zhang, L., Liu, J.Z., Dean, D., et al., 2006. A three-dimensional fractal analysis method for quantifying white matter structure in human brain. *J. Neurosci. Methods* 150, 242–253.
- Zhang, L., Dean, D., Liu, J.Z., et al., in press. Quantifying degeneration of white matter in normal aging using fractal dimension. *Neurobiol. Aging* 21. doi:10.1016/j.neurobiolaging.2006.06.020.